



Comparison of Outcomes of V-Y Atasoy vs Pentagonal Advancement Flap in the Management of Fingertip Injuries Allen Type II and III in a Tertiary Hospital

Diana C. Bandong, MD, DPBO and Justiniano S. Bai, MD, FPOA

Department of Orthopedics, Baguio General Hospital and Medical Center, Benguet, Philippines

ABSTRACT

Background. Fingertip injuries are the most common traumatic conditions of the hand, affecting productivity and livelihood due to a decrease in manual labor capabilities. The V-Y Atasoy advancement flap is typically effective in managing dorsal or transverse fingertip Allen type II and III injuries but may result in complications like dog ears, flap necrosis, paresthesia, and hook nail deformities.

Objective. This paper aimed to describe the assessment, operative technique, and outcomes in patients with fingertip injury Allen type II and type III treated with the V-Y Atasoy advancement flap versus the pentagonal flap. We also aimed to compare the outcomes and complications associated with each technique.

Methodology. A randomized controlled trial was done among patients with fingertip injury Allen type II and III who were admitted to a tertiary hospital.

Results. There were no significant differences in the rates of immediate complications (flap necrosis, infection, dog ear deformity) or short-term outcomes (two-point discrimination, Semmes-Weinstein monofilament test) between the two groups. Most patients had excellent satisfaction and were able to return to work.

Conclusion. Patients of the two groups had good to excellent outcomes and had minimal complications, with no significant differences between the groups. The pentagonal flap can be an alternative to the V-Y Atasoy flap in managing fingertip injuries, especially those with a larger surface area of injury.

Keywords. fingertip injury Allen II and III, V-Y Atasoy flap, pentagonal flap

INTRODUCTION

The hand is one of the most important parts of the body for accomplishing tasks from typing reports in the office to manual labor in the streets. In the same vein, the hand is prone to work-related injuries which entail additional financial burden on the family. The goal of management is to preserve the length of the finger, minimize pain, maximize functionality, provide satisfaction, and hasten return to work. The V-Y advancement flap technique creates a triangular volar flap with its apex at the distal interphalangeal crease and its base at the margin of the amputation. It is advantageous in providing padding and good contour, and sensation. It is an outstanding reconstructive method in many distal fingertip injuries with bone exposure. However, its indication is limited, as this is only applicable to dorsal oblique and transverse types of fingertip injury, and complications can occur (dog ear, flap necrosis, paresthesia, and hook nail deformity). Due to this, modifications include leaving the donor site defect open to prevent flap necrosis, managing volar oblique amputations with the V-Y flap,

ISSN 0118-3362 (Print)
eISSN 2012-3264 (Online)
Printed in the Philippines.
Copyright© 2024 by Bandong and Bai.
Received: May 20, 2024.
Accepted: June 9, 2024.
Published Online: August 1, 2024.
<https://doi.org/10.69472/poai.2024.15>

Corresponding author: Diana C. Bandong, MD, DPBO
Medical Officer IV
Department of Orthopedics
Baguio General Hospital and Medical Center
Governor Pack Road, Baguio City, 2600,
Benguet, Philippines
Tel. No. (+074) 6617910
E-mail: ortho@bghmc.doh.gov.ph
ORCID: <https://orcid.org/0009-0000-1179-3585>



modifying the dissection of the flap to prevent tension through stretching, and dividing the vertical fibrous septa proximally. Since complications can still occur even with these modifications, the researcher introduces their modification of the V-Y Atasoy flap: the Pentagonal advancement flap. Two longitudinal parallel incisions were made the same width apart as the width of the defect. These were connected proximally with a V-shaped incision with an apex >60 degrees. The nail was sutured to the distal subcuticular edge of the flap using an interrupted technique, and the donor site was left open to heal with a secondary intention of preventing flap necrosis. This shape is intended for complete coverage of the defect while avoiding dog ears from excess skin and preventing flap necrosis from a narrow proximal apex. This study is the first to present this innovation in managing fingertip injuries.

Fingertip injuries are difficult to manage due to the complex and small anatomy of the fingertip's veins and arteries.¹ Treatment must be individualized based on patient-related factors (e.g., age) and specific wound characteristics. The goal of treatment is to restore form and function. Factors such as the cost-effectiveness of the procedure, recovery duration, and the surgeon's technical skill should also be considered.²

Allen's classification is commonly used to describe the level of fingertip amputation.³ Type 1 injuries involve the pulp only. Type 2 injuries include the pulp and nail bed. Type 3 injuries include partial loss of the distal phalanx plus corresponding losses of pulp and nail. Type 4 injuries involve the lunula, distal phalanx, and pulp with nail bed loss.⁴ Proper classification guides the clinician on the appropriate management. Type I injury may heal through secondary intention. On the other hand, for Type II injuries, the Atasoy V-Y advancement flap is frequently used.⁵ A type III injury can be managed with a composite graft, local flap, cross-finger flap, finger replantation, revision amputation, or pocket technique.⁶ Type IV Allen classification would most likely need nailbed grafting, microvascular replantation, or amputation.⁷ Complications can result in hook nail deformities, necrosis, or a shortened finger.⁸

This paper aimed to describe the operative technique and compare the outcomes and complication rates of patients with fingertip injury Allen type II and type III treated with the V-Y Atasoy advancement flap versus the pentagonal flap. There was no local data found on the V-Y advancement flap for fingertip injuries in the Philippines, nor any studies on the pentagonal flap.

METHODOLOGY

This was a randomized controlled trial, open-label, non-inferiority study with an experimental and a control group. The participants were randomly allocated to two groups; one group was managed with the pentagonal flap and the other group was managed using the V-Y Atasoy technique. Randomization was done through simple random sampling by generating random numbers using OpenEpi version 3.01. The

researcher provided the number coding in sealed envelopes to patients who met the inclusion criteria. Ethical approval was obtained from the Ethics Review Committee, Baguio General Hospital and Medical Center, before the commencement of the study.

Inclusion criteria

1. Allen fingertip injury type II and III
2. Patients aged 19 to 60 years old
3. Intact volar skin distal to the distal digital crease
4. Transverse or dorsal oblique fingertip injury
5. Fingertip injuries in the index to small finger
6. ASA Physical Classification 1 and 2

Exclusion criteria

1. No consent
2. Volar fingertip injury
3. Multiple fractures on the same site
4. Existing infection on the same site
5. Presence of profound scarring on the fingertip
6. Preexisting nerve injury on the same hand
7. Direct-to-operating room patients with multiple injuries
8. Patients with co-morbidities (e.g., hypertension, diabetes mellitus)

The target sample size of 16 was based on the successful outcomes of previous cases using pentagonal flap and outcomes of cases treated with bilateral V-Y rotation flap³ and computed using a 95% confidence interval, 80% power, 5% margin of error, and odds ratio of 76 via OPEN-EPI version 3.1.

Between February 2022 to September 2023, 15 patients with fingertip injury Allen type II and III who fulfilled the inclusion criteria were randomized. The ages ranged between 20 to 50 years old. There were nine men and six women included in the study.

The wounds were initially assessed, irrigated, and dressed. Anterior-posterior, oblique, and lateral X-rays were taken to document any bony involvement. Patients were screened and advised of the need for admission and surgery. After the patient consented to admission, the study was introduced by the primary researcher. The patient's case, the study, the procedure, the attending surgeon, and any risks and benefits were thoroughly explained. The patient provided the informed consent in the language or dialect they preferred. The surgical procedure was conducted by the orthopedic hand rotator during their term of rotation. The patients were blinded regarding the procedure done to them. The author also either conducted or assisted the surgery depending on her current rotation and assisted in the patients' postoperative follow-up.

Immediate operative debridement and flap reconstruction were performed on all subjects using a digital nerve block with lidocaine. For the V-Y Atasoy flap technique, the incision was a V-shape at the volar area of the finger with the width of

the distal edge equal to the nail bed and the apex not passing proximally to the distal digital crease. The incision was made through the skin continuing it out deep down to the bone dividing the periosteal attachments. The deep surface of the flap was freed completely from the underlying tendon sheath. The lateral subcutaneous tissues that contained the pedicle of the flap were spread apart with micro-scissors. The flap was advanced and closed using a monofilament 3-0 or 4-0 suture starting at the apex creating the vertical stem of the “Y” (Figure 1).

For the pentagonal flap, the shape of the flap was modified by cutting longitudinal parallel lines of the same width as the recipient site defect on the distal volar skin. The V-shaped cut with an apex >60 degrees was made connecting the

longitudinal incisions proximally, forming a pentagon-shaped flap. The fibrous septa anchoring the skin to deeper structures was delicately divided. The subcutaneous tissues were detached from the periosteum and flexor tendon sheath to free the deep margin of the flap. The full-thickness skin flap was then advanced to cover the exposed bone, and the neurovascular bundles were maintained intact. The flap was carefully shaped and contoured to the fingertip by suturing with a Monocryl 3-0 suture. The flap was then sutured to the nail. The V-shaped donor site defect was left open to heal with a second intention to prevent neurovascular impingement to avoid flap necrosis (Figures 2 and 3).

Care was taken to monitor vital signs, maintain sterility, achieve hemostasis, and control pain during and after the procedure. The patient started taking antibiotics upon admission to the emergency room until seven days postoperatively to prevent infection. The open wounds were dressed with a single layer of Xeroform, followed by a layer of wet and dry dressing. Xeroform is a nonadherent fine mesh gauze that has bacteriostatic properties. It also has occlusive properties, thereby providing a moist environment conducive to healing and protecting the wound from contamination.

At the ward, patients were monitored for 24 to 48 hours and any complications (flap necrosis, infection, and dog ear deformity) were recorded as immediate outcomes. Flap viability was monitored by noting circulation on the flap through capillary refill, temperature, and color. Patients were discharged if the surgical site improved with no signs of complications.

On the first follow-up visit three to five days postoperatively, the dressing was removed but the Xeroform gauze was left intact. The patient was then asked to bathe the finger in a warm saline bath once daily for one minute then dress the digit with dry gauze. The Xeroform gauze was left covering the defect and if these instructions were carefully followed, abscess formation could be avoided.

Sensation, scar appearance, functional outcomes (via the Sollerman hand function test, Figure 6), satisfaction, and return to work were assessed at two weeks, one month, and three months post-operatively. The sensory function was

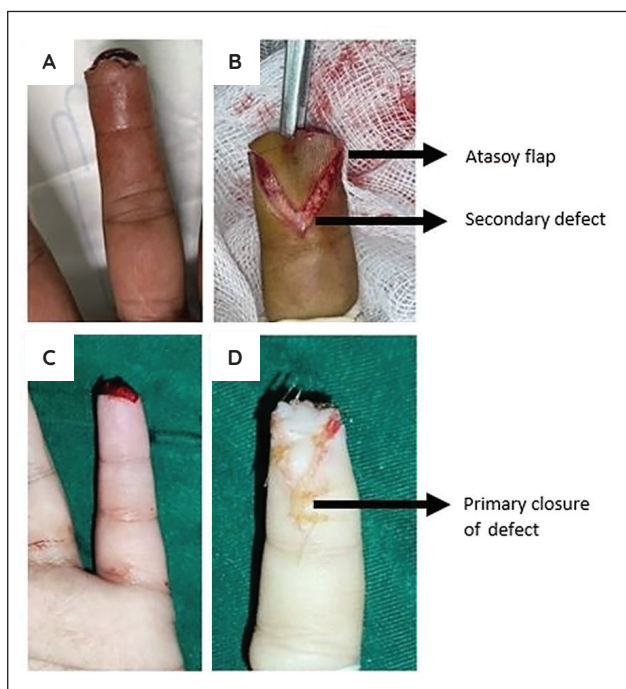


Figure 1. Intra-operative V-Y Atasoy Flap. Preoperative image (A). Intraoperative image showing the flap advancement, with a secondary defect left open (B). Preoperative image (C). Intraoperative image showing the sutured “Y” shape after primary closure of the defect (D).

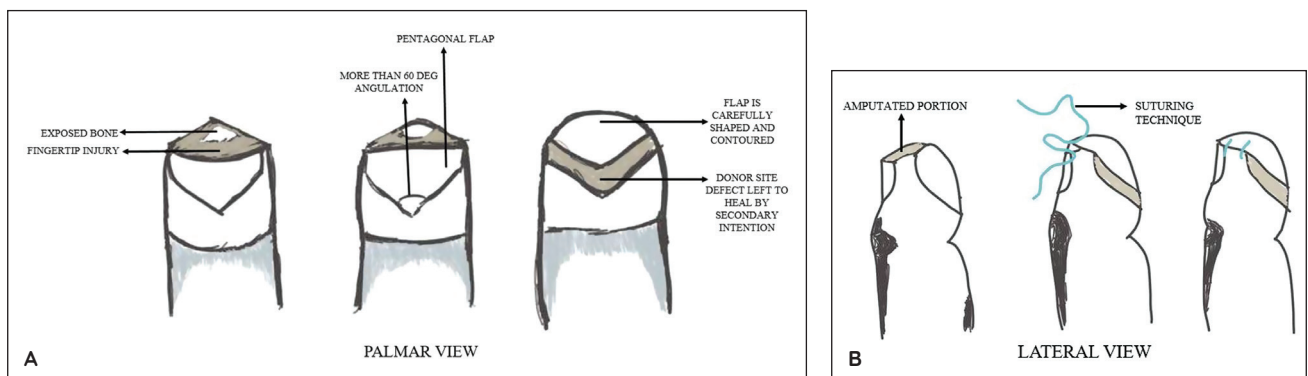


Figure 2. Pentagonal Advancement Flap Diagram. Palmar view showing the longitudinal parallel incisions and the V-shaped incision, and the advancement of the pentagonal flap (A). Lateral view showing the suturing technique to the nail (B).

measured using the static two-point discrimination test (Figure 6) and Semmes-Weinstein monofilaments (Figure 7). Patient satisfaction was self-reported using a questionnaire asking them to rate their experience as excellent, good, fair, or poor. These assessments were conducted by the resident and researcher during outpatient follow-ups.

Descriptive and inferential statistics were utilized for data analysis. The chi-square test of homogeneity was used to compare the values between the pentagonal flap and the V-Y Atasoy flap. A t-test was used to compare the values between sensation, functional outcome, satisfaction, and return to work. A significant *p*-value was set at ≤ 0.05 . Data processing was done through OpenEpi Version 3.1 (Open-Source Epidemiologic Statistics for Public Health).

RESULTS

The mean age of the participants was 32 years ($n = 15$) (Table 1). Most patients were in the age range of 19 to 30 years ($n = 8$). More patients were men ($n = 9$) and the most common occupation was laborer ($n = 6$). For immediate outcomes, there was no significant difference in the rate of complications. Flap necrosis occurred in two patients from each group ($p = 0.875$). Minor early infections occurred in one patient from each group ($p = 0.919$), resolving with wound care and oral antibiotics. Dog ear deformities occurred in three patients in the Atasoy group and one patient in the Pentagonal group ($p = 0.310$) (Table 2).

Wounds were completely healed on peeling off the Xeroform gauze after 10 to 12 days. After two weeks, patients in the

Table 1. Clinical and demographic profile of adult patients admitted with fingertip injury

		Pentagonal ($n = 7$)	V-Y Atasoy ($n = 8$)	Total	%	<i>p</i> -value*
Age	20-30 y/o	2	6	8	53.33	0.193
	31-40 y/o	2	1	3	20	
	41-50 y/o	3	1	4	26.67	
Sex	Male	4	5	9	60	0.832
	Female	3	3	6	40	
Work	Professional	3	1	4	26.67	0.404
	Clerical	2	3	5	33.33	
	Laborer	2	4	6	40	
Handedness	Right	6	6	12	80	0.604
	Left	1	2	3	20	

**p*-value as calculated by chi-square

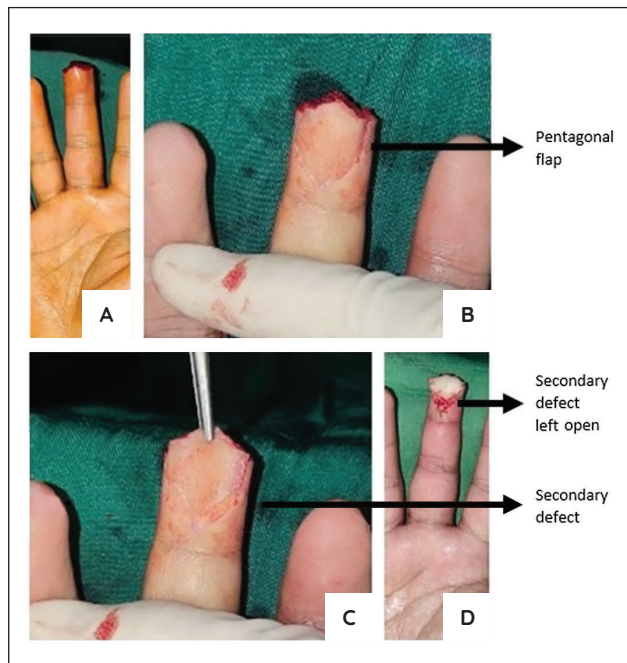


Figure 3. Intra-operative Pentagonal Advancement Flap. Preoperative image (A). Incisions were made outlining the pentagonal flap (B). The pentagonal flap was advanced, leaving a secondary defect (C). Appearance of the pentagonal flap and secondary defect after suturing (D).

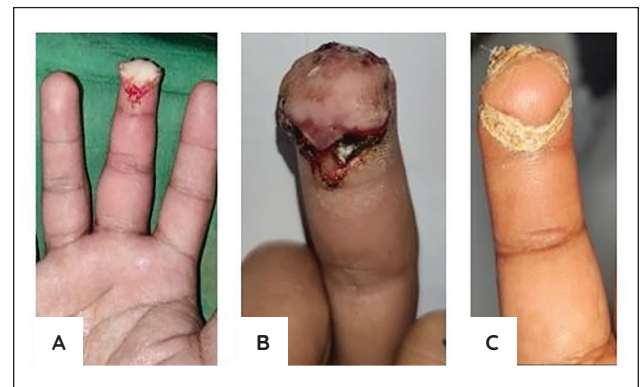


Figure 4. Outcomes of Pentagonal flap. Immediate postoperatively (A); 48 hours postoperatively (B); One month postoperatively (C).

Table 2. Comparing the complications of V-Y Atasoy flap vs Pentagonal flap after 24-48 hours

	Pentagonal	V-Y Atasoy	<i>p</i> -value*
Flap necrosis	2	2	0.875
Early infection	1	1	0.919
Dog ear deformity	1	3	0.310

**p*-value as calculated by chi-square

Pentagonal group had a non-significantly higher rate of scar tenderness compared to the Atasoy group ($p = 0.184$). Most patients scored a grade of 3 in 2-point discrimination, with no significant difference between the groups ($p = 0.875$). There was also no significant difference in the results of Semmes-Weinstein monofilament testing ($p = 0.411$) (Table 3).

Satisfaction rates were similar between the two groups at one month postoperatively ($p = 0.408$). Most patients in each group ($n = 5$) reported a score of 4 on the Sollerman hand function test (able to carry out tasks without any difficulty) ($p = 0.403$). At the end of the follow-ups, patients were able to return to their work without limitations ($p = 0.385$) (Table 4). At the final follow-up, one patient from each group had improvement in their two-point discrimination ($p = 0.454$). Likewise, one patient from each group improved by one grade when tested with the Semmes-Weinstein monofilaments ($p = 0.434$). There were no significant differences between the groups (Table 5).

There was no significant difference in the rates of nail deformity, insensate digit, cold intolerance/hyperesthesia, or late infection between the two groups ($p = 0.310$) (Table 6).

The average time to re-epithelization of the Pentagonal flap was 3.7 weeks. No patient was lost to follow-up.

DISCUSSION

The classic V-Y advancement flap, also known as the Atasoy flap, is frequently used for the reconstruction of fingertip amputations with exposed bone. It is applicable in dorsal oblique and transverse amputations, supplying sensate skin and robust subcutaneous tissue thanks to the preservation of the distal branches of the digital vessels and nerves.⁹

The V-Y advancement flap was originally described by Tranquilli-Leali in 1935 but was first reported in the United States by Atasoy et al. in 1970. In the study done by Tranquilli-Leali to review the anatomy of the fingertip and compare two flap techniques, it was proven that the flap was supplied by the anastomotic connections via the fibro-osseous hiatus between the terminal branches of the dorsal nail-bed arcades and palmar digital arteries.¹⁰

Previous studies have reported good outcomes with the

Table 3. Comparing the sensation outcomes of V-Y Atasoy Flap vs Pentagonal Flap after two weeks

		Pentagonal	V-Y Atasoy	p-value
Scar tenderness		3	1	0.184
2-Point Discrimination				
Grade	Interpretation			
3	<6 mm	5	6	0.875
2	6-10 mm	2	2	
1	11-15 mm	0	0	
0	>15 mm	0	0	
Semmes-Weinstein Monofilament test				
Grade	Interpretation			
6	Normal	3	5	0.411
5	Diminished light touch	3	1	
4	Diminished protective sensation	1	2	
3	Loss of protective sensation	0	0	
2	Loss of protective sensation	0	0	
1	Deep pressure sensation only	0	0	
0	Loss of sensation	0	0	

*p-value as calculated by t-test

Table 4. Comparing the satisfaction, Sollerman hand function, and return to work of V-Y Atasoy flap vs Pentagonal flap after one month

		Pentagonal	V-Y Atasoy	p-value
Satisfaction	Excellent	4	4	0.408
	Good	1	2	
	Fair	1	1	
	Poor	1	1	
Sollerman hand function test	4 - the task was carried out without any difficulty	5	5	0.403
	3 - the task was completed, but with slight difficulty	2	3	
	2 - task was completed, but with great difficulty	0	0	
	1 - task was partially performed within 60 seconds	0	0	
	0 - patient could not carry out the task	0	0	
Return to work	Soft labor/office work	5	4	0.385
	Hard labor	2	4	

*p-value as calculated by t-test

Table 5. Comparing the sensation outcomes of V-Y Atasoy flap vs Pentagonal flap after three months

		Pentagonal	V-Y Atasoy	p-value
2-Point Discrimination				
Grade	Interpretation			
3	<6 mm	6	7	0.454
2	6-10 mm	1	1	
1	11-15 mm	0	0	
0	>15 mm	0	0	
Semmes-Weinstein Monofilament test				
Grade	Interpretation			
6	Normal	4	6	0.434
5	Diminished light touch	2	1	
4	Diminished protective sensation	1	1	
3	Loss of protective sensation	0	0	
2	Loss of protective sensation	0	0	
1	Deep pressure sensation only	0	0	
0	Loss of sensation	0	0	

*p-value as calculated by t-test

Table 6. Late complications of V-Y Atasoy flap vs Pentagonal flap

Complications	Pentagonal	V-Y Atasoy	p-value
Nail deformity (hooked nail)	1	1	0.310
Insensate digit and stiff fingers	0	0	
Cold intolerance/hyperesthesia (Figure 8)	1	2	
Late infection	1	1	

technique. Viciana reported on a 12-year-old who sustained a transverse amputation of the distal third of the left ring finger distal phalanx treated with an Atasoy flap. They report good color and sensibility after seven days, and full range of motion after 14 days. Two-point discrimination was 5 mm throughout.¹¹ The current study found that most patients had a grade 3 two-point discrimination (<6 mm) with the rest falling under grade 2 (6 to 10 mm).

Another study done by Ozyigit et.al. presented five dorsal V-Y advancement flaps done in patients aged 25 to 46 and presented results after 12 to 24 months. All flaps survived and a full range of movement was retained in the affected digit. All patients were satisfied and used their digits without difficulty. The mean static two-point discrimination differed on both sides of the finger but was satisfactory. The fingertips looked excellent, and no patient had any pain. All patients returned to work by the 21st day. No dysesthesia or hyperesthesia was seen in any patient.¹² In this study, none of the patients developed an insensate digit; however, three patients developed cold intolerance (Pentagonal $n = 1$, Atasoy $n = 2$).

Modifications of the V-Y Atasoy advancement flap were done to improve the outcome. In a study made by Thoma, the donor site defect was left open and allowed to heal by secondary intention instead of closing the donor site in a Y pattern.¹³ To cover the bone, the base of the triangle was loosely sutured to the nail bed. Small wound gaps are of no concern for this open area heals adequately by secondary intention without the burden of tight closure. Another

study used the V-Y rotation advancement flap bilaterally for fingertip amputations. Rotation made this flap more mobile and easier to cover larger defects in all amputation planes. The follow-up period was 3 months to 2 years. There was neither total nor partial flap loss. Physical therapy was not indicated because the fingers had a full range of motion. No reports of cold intolerance or scar hypersensitivity. No stiffness of the PIP joint was seen. No hooked nails occurred in patients who have remaining nail matrices. Satisfactory function and sensation on the amputation stump were obtained. Most patients returned to work in about 1.5–2.5 weeks (the mean time off work was 9 days).⁸

The need for a tension-free closure is emphasized in many sources. The flap is at risk for necrosis if tension-free closure is not achieved. The problem may be because of the swelling that occurs after closure. Also, the distal nail bed may be dragged in the anterior direction, forming a hook nail deformity. The author undertook this study due to the number of cases treated with classical Atasoy flap that necrosed.

In this study, outcomes were similar between the Pentagonal flap and the V-Y Atasoy flap. There were minimal complications between the two groups. The Pentagonal flap was easier to shape to cover most of the injury and faster to close since the surgeon needed to close only the distal portion. However, during dressing changes, it was easier to change those in the Atasoy group since all the corners were closed. Most patients in this study had good wound healing and were able to return to work without limitations. The rate of flap necrosis in both

groups may be attributed to the surgeon's technique and the study's small population.

Limitations of the study include a small population, different surgeons, and anatomical variations. These may have caused varying outcomes and rates of healing among the patients.

CONCLUSION

Patients of the two groups had good to excellent outcomes and had minimal complications, with no significant differences between the groups. The pentagonal flap can be an alternative to the V-Y Atasoy flap in managing fingertip injuries, especially those with a larger surface area of injury. Further study is recommended with larger populations.

STATEMENT OF AUTHORSHIP

All authors certified fulfillment of ICMJE authorship criteria.

AUTHORS DISCLOSURE

The authors declared no conflict of interest.

FUNDING SOURCE

None.

REFERENCES

1. Chang J, Vernadakis AJ, McClellan WT. Fingertip injuries. *Clin Occup Environ Med.* 2006;5(2):413-22. ix. PMID: 16647658 DOI: 10.1016/j.coem.2005.11.010
2. Martin C, Gonzalez del Pino J. Controversies in the treatment of fingertip amputations. Conservative versus surgical reconstruction. *Clin Orthop Relat Res.* 1998(353):63-73. PMID: 9728160 DOI: 10.1097/00003086-199808000-00008
3. Sungur N, Kankaya Y, Yildiz K, et al. Bilateral V-Y rotation advancement flap for fingertip amputations. *Hand (N Y).* 2012;7(1):79-85. PMID: 23448959 PMCID: PMC3280365 DOI: 10.1007/s11552-011-9389-6
4. Hwang E, Park BH, Song SY, et al. Fingertip reconstruction with simultaneous flaps and nail bed grafts following amputation. *J Hand Surg Am.* 2013;38(7):1307-14. PMID: 23707593 DOI: 10.1016/j.jhsa.2013.03.032
5. Pencle FJ, Waseem M. Fingertip Injuries. In *StatPearls* [Internet]. Treasure Island (FL): StatPearls Publishing; 2020.
6. Spyropoulou GA, Shih HS, Jeng SF. Free pulp transfer for fingertip reconstruction-the algorithm for complicated Allen fingertip defect. *Plast Reconstr Surg Glob Open.* 2015;3(12):e584. PMID: 26894009 PMCID: PMC4727693 DOI: 10.1097/GOX.0000000000000569
7. Malshikare VA. Graft reposition on flap: mid-term result in Allen type IV amputation. *J Hand Surg Asian Pac Vol.* 2019;24(2):219-23. PMID: 31035869 DOI: 10.1142/S2424835519500292
8. Jung MS, Lim YK, Hong YT, Kim HN. Treatment of fingertip amputation in adults by palmar pocketing of the amputated part. *Arch Plast Surg.* 2012;39(4):404-10. PMID: 22872846 PMCID: PMC3408288 DOI: 10.5999/aps.2012.39.4.404
9. Martin-Playa P, Foo A. Approach to fingertip injuries. *Clin Plast Surg.* 2019;46(3):275-83. PMID: 31103072 DOI: 10.1016/j.cps.2019.02.001
10. Gharb BB, Rampazzo A, Armijo BS, et al. Tranquilli-Leali or Atasoy flap: an anatomical cadaveric study. *J Plast Reconstr Aesthet Surg.* 2010;63(4):681-5. PMID: 19285932 DOI: 10.1016/j.bjps.2008.12.028
11. Viciano EJ, Lessard AS. Expanded utilization of the digital Atasoy flap. *Plast Reconstr Surg Glob Open.* 2018;6(12):e2049. PMID: 30656123 PMCID: PMC6326594 DOI: 10.1097/GOX.0000000000002049
12. Ozyigit MT, Turkaslan T, Ozsoy Z. Dorsal V-Y advancement flap for amputations of the fingertips. *Scand J Plast Reconstr Surg Hand Surg.* 2007;41(6):315-9. PMID: 17952813 DOI: 10.1080/02844310701463357
13. Thoma A, Vartija LK. Making the V-Y advancement flap safer in fingertip amputations. *Can J Plast Surg.* 2010;18(4):e47-9. PMID: 22131847 PMCID: PMC300611

Disclaimer. All articles and materials published in PJO are solely those of the authors. Statements and opinions expressed by authors do not represent those of the editor/s of the Philippine Journal of Orthopaedics or of its publisher, the Philippine Orthopaedic Association.